



ARAB ASSOCIATION OF PAEDIATRIC SURGEONS

intersax 1993

**The Proceeding Book of the  
4th Congress of the Arab Association  
of Paediatric Surgeons**

*The full text of the refereed papers presented at the Congress  
held in Dubai, U.A.E.  
on 26-28 October 1993*

Prof. Adil Lutfi  
*Editor*

Compliments from:  
GlaxoWellcome

**The Proceeding Book of the  
4th Congress of the Arab Association  
of Paediatric Surgeons**

*The full text of the refereed papers presented at the Congress  
held in Dubai, U.A.E.  
on 26-28 October 1993*

Prof. Adil Lutfi  
*Editor*

**The Proceeding Book of the  
4th Congress of the Arab Association  
of Paediatric Surgeons**

*The full text of the refereed papers presented at the Congress*

*held in Dubai, U.A.E.*

*on 26-28 October 1993*

Prof. Adil Lutfi  
*Editor*

REFERENCES:

1. Coran AG, Polley TZ. Surgical Management of Ambiguous Genitalia in the Infant and Child. *J Ped. Surg.*, 1991; 26:812-820.
2. Donahoe P. The Diagnosis and Treatment of Infants with Intersex Abnormalities. *Pediatr. Clin. North Am.*, 1987; VV.34, No.5: 1333-1348.
3. Pagon R. Diagnostic Approach to the Newborn with Ambiguous Genitalia. *Pediatr. Clin. North Am.*, 1987; V. 34, No. 4: 1019-1031.
4. Mc Cauley E. Disorders of Sexual Differentiation and Development- Psychological Aspects. *Pediatr. Clin. North Am.*, 1990; V. 37, No. 6: 1405-1420.
5. Nixon H, O'Donnell B. Intersex. In: *The Essentials of Paediatric Surgery*. London: WH MB Ltd., 1976; 222-227.
6. Bissada NK, Sakati N, Woodhouse N, Morcos R. One Stage Complete Genital Reconstruction for Patients with Congenital Adrenal Hyperplasia. *J. Urol.*, 1987; 137: 703-705.
7. David M, Forest MG. Prenatal Treatment of Congenital Adrenal Hyperplasia Resulting from 21-Hydroxylase Deficiency. *J Pediatr.*, 1984; 105: 799-803.
8. Pang S, Pollack M, Marshall R, Imken LD. Prenatal Treatment of Congenital Adrenal Hyperplasia due to 21-Hydroxylase Deficiency. *N. Engl. J Med.*, 1990; 322: 111-114.

## INTERSEX: SURGICAL AND ETHICAL ASPECTS

*Jamal Y., Meshref S, Daleel Al Rahman J, Jamal H., Al-Ghamdi A.*

### SUMMARY

Intersex is a complex problem not only in its surgical correction but more critical in the decision of the sex assignment.

We manage 46 patients with intersex problem over the period from 1985 to 1993. 24 patients (52.17%) with female pseudohermaphroditism (FPHP), 1 patient (2.17%) with true hermaphroditism (TH), and 21 patients (45.65%) with male pseudohermaphroditism (MPHP).

We present our experience in the surgical reconstruction of male and female genitalia in concordant with the sex assignment, with particular emphasis on the improved outcome of male genital reconstruction by utilizing the different adjunctive measures to augment the penis, such as supra pubic lipectomy, liposuction and IM and local administration of the androgenic hormones.

Additionally we discussed some ethical aspects concerning sex assignment which is applicable to our community.

**KEY WORDS:** Male and female pseudohermaphroditism - true hermaphroditism - Surgical Management - Saudi Arabia

### INTRODUCTION

Intersex is a complex problem which needs prompt and extensive laboratory, radiological and endoscopic workup to conclude with the appropriate sex assignment, in turn this decision leads to a further extensive surgical corrective procedure concordant with the sex assignment<sup>(1-6)</sup>. It is generally believed that reconstruction of female genitalia is easier than reconstruction of male genitalia but the increasing experience with the different augmenting penile measures, including suprapubic lipectomy, liposuction and pharmacological preparation, improve the outcome of reconstruction of male genitalia<sup>(5-8)</sup>.

The aims of this paper are: Presentation of the pattern of intersex problem in our area (Western province of Saudi Arabia), to present our experience in corrective genital surgical procedure for male and female patient according to the final sex assignment and to discuss some ethical aspects related to our community in management of intersex.

Correspondence to : Dr. Yasir Saleh Jamal, Department of Surgery, King Abdulaziz University Hospital, P.O. Box 6615, Jeddah 21452, Saudi Arabia

#### PATIENTS AND METHOD

Forty six patients were born in, or referred to our hospital, King Abdulaziz University Hospital with intersex problem over the period from 1985 - 1993. 24 with female pseudohermaphroditism, 1 with true pseudohermaphroditism and 21 with male pseudohermaphroditism.

#### **Female Pseudohermaphroditism (FPHP)**

24 patients included in this group.

20 patients were having congenital adrenogenital hyperplasia (CAH). All had single stage feminizing procedures. All of them were having clitoromegaly, all of them had nerve sparing clitoroplasty, 3 were having normal vaginal orifice and 17 without external vaginal orifice but found by sinogram and urethroscopy to have vagino-urethral communication, two of them at a level higher than the external urethral sphincter, they had vaginal pull through at the age of two years. The remaining 15 had low vagino-urethral communication, they had the cutback vaginoplasty with posterior perineal flap at the age of 3-6 months. The details of the surgical treatment of the 20 patients with CAH were reported by the author in the same proceeding<sup>(9)</sup>.

The other 4 patients with FPHP were:

One was 14 years old female patient with clitoromegaly, due to maternal androgen ingestion. She needed nerve sparing clitoroplasty only (Fig. 1)

Another one 3 years old presented with ambiguous genitalia. She has clitoromegaly, scrotalized labial folds with karyotype 46XX and ovarian gonads on both sides but no uterus or tubes or vagina. Patient had nerve sparing clitoroplasty and vaginal reconstruction by the inverted phallic skin as described by Eicher<sup>(10)</sup>, all in one stage (Fig. 2 and 3).

The other two patients were having ambiguous genitalia associated with urogenital sinus abnormality, both of them had the genital reconstruction during the staged correction of the abnormality.

#### **True Hermaphrodite (TH)**

One patient two months old has large phallus and 46XX karyotype with testis and vas deferens on the right side and ovary, rudimentary uterus and tube on the left side (Fig. 4). Patient has no vagina but long sacculus prostaticus. Discussion with the parents concluded to raise the patient as boy so the ovary, uterus, tube and the sacculus prostaticus were excised. Patient had male genital reconstruction at the age of one year (release of chordee urethroplasty and scrotoplasty. Fig. 5). the lining mucosa of the sacculus prostaticus was used in the urethroplasty.

Fig.1 14 years old female patient with history of maternal androgen ingestion, causing clitoromegaly.  
A. Preoperative  
B. Postoperative (Nerve sparing clitoroplasty)

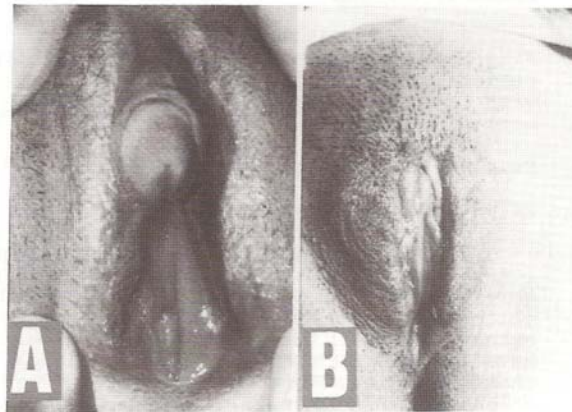


Fig. 2 : (A) Female pseudo-hermaphrodite, patient is 46 xx having ovaries, no vaginal pouch or müllerian products, (B) she had feminizing procedure [nerve sparing clitoroplasty and vaginal reconstruction utilizing the inverted phallic skin -V-].

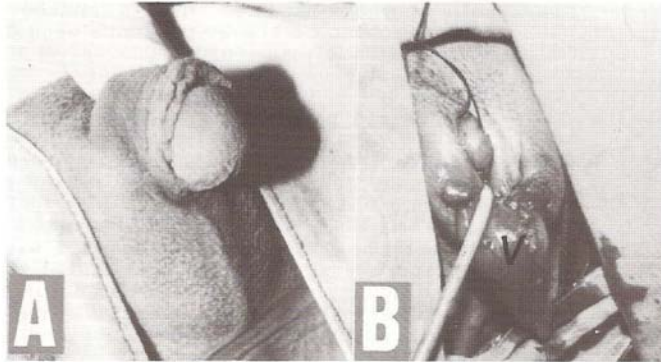
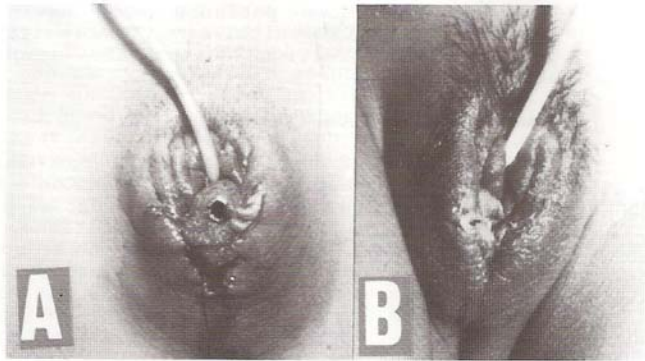


Fig. 3 Same patient of fig. 2  
(A) Immediate postoperative view with the packing of the vaginal pouch, (B) 2 weeks postoperatively.



#### Male Pseudohermaphroditism (MPHP)

21 patients were included in this group. All of them were 46 XY karyotype and having exclusively testicular tissue.

One patient of the male pseudohermaphroditism was having persistent muellerian system, he attended with good size penis bilateral undescended testis not palpable and not seen by ultrasound and CT scan. His karyotype was 46XY normal male, on exploration for the undescended testis both testis found very high, the right testis was below the right kidney and the left was high in the left iliac fossa with no vas deferens. Patient was having uterus, right and left tubes (Fig. 6) no genitoplasty required for him but excision of the muellerian products.

Twenty patients were having bifid scrotum and severe chordee of the phallus, they were sub-divided into two groups.

The first group include 8 patients who had phallus within the average size (2-3 cm long) with single meatus in the scrotoperineal region with bilateral undescended testis in 5 and unilateral undescended testis in 3 but all the undescended testes were palpable outside the abdomen. This group represent the patients with simple local genital defect in the form of posterior hypospadias with undescended testis.

The second group include 12 patients. They had phallus below the average size (1-1.5 cm long) and two orifices between the scrotal folds, one leading to the urethra the other to short vaginal pouch. 5 patients with bilateral undescended testis. This group represent the patients with incomplete testicular feminization and the 5 $\alpha$  reductase deficiency but differentiation was difficult because the necessary tests to differentiate between the two abnormalities were not available in our hospital (serum dihydrotestosterone level and androgen receptors detection). Five patients of this group were having other brother with similar problem but they are not included in this study.

All the 20 patients were treated with testosterone injection (25 mg IM every 3 weeks for 3 injections). All showed response to the injection with increase penile length ranging from 50-200%. The second group had additional local application of dihydrotestosterone ointment once daily for 6 to 8 weeks, which showed further improvement in the size of the phallus which was very satisfactory in 7 out of 12 patients (penile length showed further 200% increase). We consider this as an indication that these 7 cases were due to 5 $\alpha$  reductase deficiency (all of the 7 were having bilateral descended testes in the scrotal fold).

The 20 patients raised as male. They had release of chordee excision of the vaginal pouch (in second group), urethroplasty, orchidopexy and scrotoplasty. 15 patients had full genitoplasty in single stage and 5 had release of chordee and excision of the vaginal pouch in one stage and orchidopexy, urethroplasty and scrotoplasty in the second stage. All urethroplasty were done utilizing full thickness skin graft from the inner aspect of the upper arm. (Fig. 7,8,9,10,11).



Fig. 4 Intraoperative view of the patient with true hermaphroditism on the right side of testis (T), Vas deferens (V) on the left side ovary (O), uterus (u), tube (t) with frimbai (f).

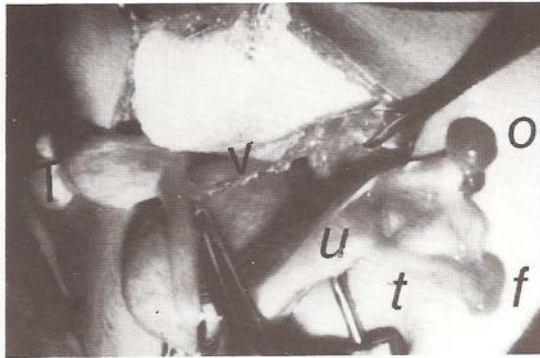

Fig. 5 Same patient of fig.4 (A) Preoperative view of external genitalia with Good size phallus. (B) After genitoplasty

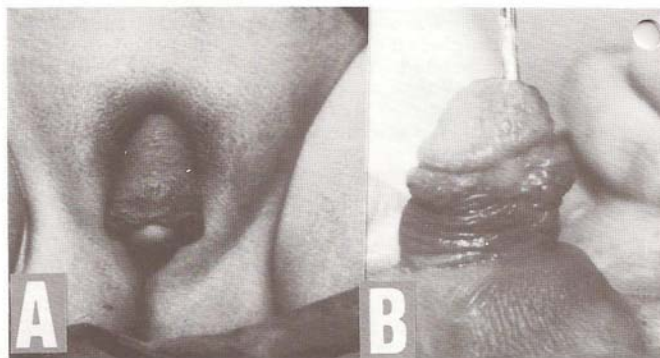
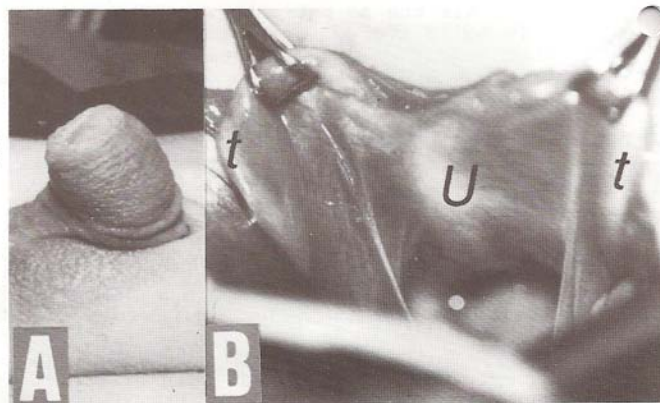


Fig. 6 Male pseudohermaphrodite with persistent mullarian system. (A) The external genitalia, (B) Intraop. view showing the uterus (u) & the tubes (t).



Two patients had liposuction of the fatty mons pubis and another two had suprapubic lipectomy for augmentation of the penile length.

#### **RESULTS**

Genital reconstruction of the female pseudohermaphroditism was very satisfactory cosmetically with good caliber vaginal passage.

The patient with true hermaphroditism has good result but he developed stricture at the site of proximal anastomosis which responded to regular urethral dilatation.

The patients of male pseudohermaphroditism showed satisfactory outcome with acceptable phallic size after the pre-operative augmentation of the Phallus by testosterone injection and local application of the dihydrotestosterone. Liposuction which was done in two patients and lipectomy of the pubic fat in two patients, improved the penile length in the four patients with an increased length of 1 cm. Six patients developed penile fistula which was closed in two layers as a day case. Three patients developed urethral stenosis. Two responded to urethral dilatation but one was severe scar former he had 6 operations 3 times proximal perineal urethrostomy to relieve his urinary retention and 3 times urethroplasty at the site of the fibrosis.

#### **DISCUSSION:**

Intersex problem is uncommon abnormality which include wide varieties of defective sex differentiation. Several pattern of classification were suggested to simplify the understanding and management of the different intersex variants but the most widely used classification based on the gonadal tissue present, with sub-classification according to the etiology<sup>(1)</sup>.

In our patients the female pseudohermaphroditism represented 52.17% (24 patients) of all patients, 83.33% (20 patients) of them were due to CAH, while the male pseudohermaphroditism represented 45.65% (21 patients) and the true hermaphroditism account for 2.17% (1 patient). We did not have any patient with the gonadal dysgenesis. This pattern is similar to the other reported pattern in showing that FPHP is the commonest cause of intersex, particularly CAH. But MPHP is higher than the other reports<sup>(1-4)</sup>. The presence of one patient with true hermaphroditism and the absence of any case with gonadal dysgenesis may indicate that these types of intersex in our community are very rare.

Management of patient with the intersex is difficult and complex matter as it involves many parameters, on one hand the decision of sex assignment in the view of the social and religious factors of the different communities, on the other hand the structural abnormality particularly the external genitalia and the feasibility for surgical correction to concord with sex assignment.

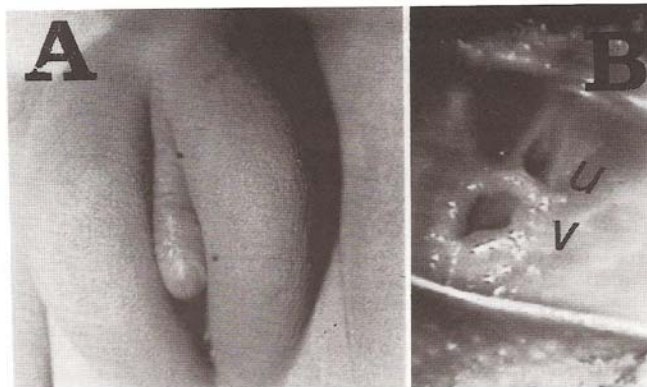


Fig. 7 Male pseudohermaphrodite  
A. the external genitalia with small phallus  
B. Patient has short vaginal pouch with hymen, (u) urethral meatus, (v) vaginal opening

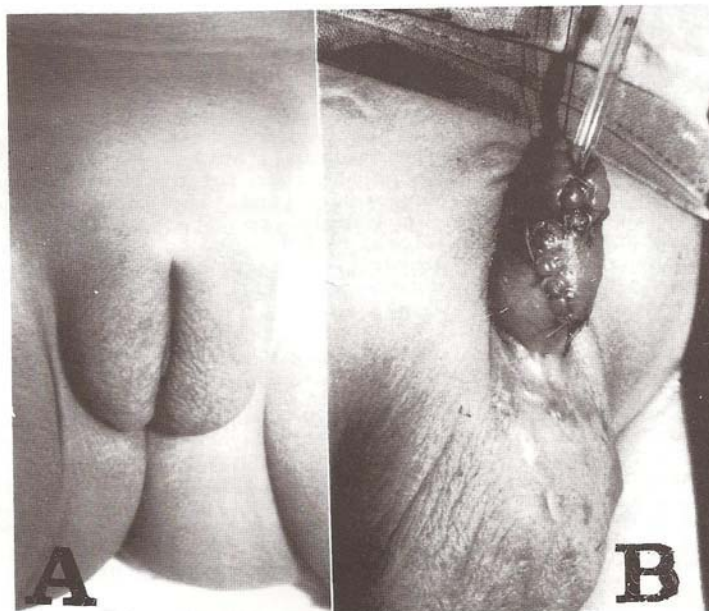


Fig. 8 Same patient of Fig. 7  
A. Preoperative view  
B. full genitoplasty after testosterone treatment

We believe as others that early sex assignment and early surgical correction in accordance to the assignment are of paramount importance for the parents and the baby<sup>(1-4,11,12)</sup>. Parents should have, as early as possible, clear information concerning sex assignment of their baby which in turn will be reflected on the normal gender identity of the child and normal relationship with his parents. Early surgical correction will firmly fix the gender identity in the mind of the child and his parents.

Our experience in surgical correction of the male and female genital reconstruction shows satisfactory results. Patient assigned as female had feminizing procedure which lead to female genitalia which is cosmetically satisfactory and pleasing to the parents with good vaginal caliber including the case of the vaginal reconstruction with the inverted phallic skin which we feel it is good option if this type of skin flap is available and adequate which will be free of stenosis that might be associated with the skin graft vaginal reconstruction.

Systemic and local administration of androgenic preparations was effective in improving the penile size in all of our (MPHP) patients but with variable degree of response. The penile size increased twice to four times of its original size particularly when both systemic and local administration were utilized.

The variability in the response to androgens in different reports<sup>(5,6)</sup> probably due to the variability in the presence and the type of the underlying intersex problem. We believe the lesser the response, the more likely the possibility of the intersex problem due to the quantitative or qualitative androgenic receptors defects. We recommend when the test for differentiation between the 5  $\alpha$ -reductase deficiency and the partial testicular feminization are not available to start with the use of testosterone (systemic, local or both) and to evaluate the response and then to use the dihydrotestosterone which will give better response in case of 5  $\alpha$ -reductase deficiency.

Our policy in the sex assignment of our patients was as the following:

We propose to classify the sex determining factors into primary and secondary factors (Table 1) because the primary factors will affect the secondary factors but not the vice versa. If both primary factors are normal to one sex, person should be assigned to that sex. On the other hand, if both types of gonadal tissues or both male and female genetic material present in the same person, then either sex can be considered and the decision will be dependent on the secondary sex determining factors.

Table 1. SEX DETERMINING FACTORS

Primary Sex Determining Factors	Secondary Sex Determining Factors
Chromosomes 46 XX or 46 XY Gonads Ovaries or Testes	External Genital Structures Internal Genital Structures Expected future sexual function Expected future fertility Socio-psychological status includes: <ul style="list-style-type: none"> <li>- Age at presentation</li> <li>- Sex of rearing at presentation</li> <li>- Parents wishes</li> <li>- Patient's feelings and wishes</li> </ul>

**FPHP** we raise the patients as female and early subject them to feminizing procedure. There is no controversy in the different communities to raise the FPHP as female.

**TH** sex assignment in this group is variable as the patient having the gonads of both sexes and might be having 46 XX or 46 XY or 46 XY/46 XX. The conflict at the primary sex determining factor makes the sex assignment dependent on careful evaluation of the secondary sex determining factors to assign the patient to the most appropriate sex concordant with the expected future sex role. The plan of sex assignment suggested by Luks et al<sup>(11)</sup> in true hermaphroditism depending on the external genital structure is helpful classification in patients presenting early during infancy. But when the case presented late, this requires further consideration of the secondary sex determining factors. In cases of TH and gonadal dysgenesis, it is reasonable to consider assignment to either sex because the patient has major conflict at the primary level of sex determination.

**MPHP** we raise patients with MPHP as male with one exception only, this is the patients with complete testicular feminization who are usually present late and have normal female external genitalia.

The current practice in other communities is to raise the MPHP who has inadequate phallus as female but this concept is difficult to apply in our community and even we found that some reports in the recent years showing changing trend in the concept of feminizing the male patients with inadequate phallus, as stated by Reilly and Van seters<sup>(13-14)</sup>

Reilly conclude his article with the statement, "Two main conclusions may be drawn from our series: a small penis does not preclude normal male role and micropenis or microphallus alone should not dictate a female gender reassignment in infancy".

Also, Van seters stated "It is therefore not obligatory to decide at birth that a newborn genetically male baby with micropenis should be raised as girl, as sometimes recommended. If the decision goes in the direction of rearing as a boy, careful psychological support for both parents and child is strongly advised, also, the possibility of early testosterone treatment or surgical elongation should be considered".

So, our policy in raising the patient with inadequate phallus as a male based on several factors related to social and religious obligation in our community which was supported by the satisfactory outcome of the surgical correction of our patients with MPHP and further supported with the changing trend in the management of these cases in the other communities where they recommend recently the male role for these cases.

We summarize the social and religious factors as following:

1. It was found that the people in our community do not accept the concept of the sex reassignment and they refuse to marry the surgically feminized sex re-assigned person. (Summary 1)
2. Religious leaders were asked about the sex change of MPHP with inadequate phallus to a female, they rejected strongly the concept because they consider it unnecessary change in the God's creation and it is against the purpose of creating us as male and female and it would not result in normal female capable of reproduction. And additionally they condemned it as it leads to several changes in the religious commitments and the rights of the persons including the financial rights of the person and his family. (Summary 2). They consider the situation as homosexual marriage when this person marry another male. Additionally, they consider the possibility of the invention of new treatment which can treat such intersex abnormality.

In summary, we believe that sex reassignment of the genetically male patient with inadequate phallus is not applicable to our community as the reassigned female might suffer the rejection and would not live as normal female so he should be raised as male and we should reconstruct his genitalia as male and we should use all the available surgical techniques (penile lengthening) and pharmacological measures (androgenic hormones) to improve the inadequacy of the phallus. Additionally, we should train them when they marry to adapt the special position to help their sexual function. These measures can be of great help to the patient to live as male<sup>(13-14)</sup>.

### Summary 1

Questionnaire was conducted to identify the attitude of the people in our community towards sex reassignment of MPHP patient with the micropenis.

100 persons participate in this questionnaire. They were physicians and final year medical students. The subject was explained and the following questions were asked:

Question 1: What's your opinion of such sex reassignment?

All the 100 participants did not accept the concept of the sex reassignment.

Question 2: Would you accept to marry reassigned female if you know before hand.

All of them refused to marry reassigned female.

Question 3: Would you continue the marriage with reassigned female if you know after the marriage?

92 participants would not continue in such marriage and 8 participants were sympathetic with such female and could not decide whether to continue or not.

Justification for their refusal to the concept of the sex reassignment and rejection to marry sex reassigned female.

1. Reassignment is against the religious instructions as it is a change in the God's creation.
2. This change will lead to alterations of the religious commitments
3. This change will lead to alterations in the reassigned person's right and his family
4. If this reassigned person marry a male, it is homosexual marriage.
5. The reassigned person will not be a normal female in respect to sexual function.
6. It will be infertile female.
7. This sex reassignment without the consent of the person himself as the baby is not capable and not given the chance to decide for himself.
8. Future might bring better treatment for the correction of the penile size.
9. Patient with the micropenis can live as normal male similar to the patient with impotence.

**Summary 2 Some of the religious differences between male and female:-**

1. It is obligatory for the male to perform their regular 5 times prayer in the Mosque, while for females, it is preferable to perform it at home.
  2. Male witness in the court is superior to female witness (witness of 1 male equals to witness of 2 females).
  3. Males are allowed to travel alone, while females can not travel without the presence of the close male relative (e.g. father, husband, or adult brother)
  4. Inheritance:  
When a person died, his treasure will be inherited by his particular family in determined amounts.
    - A. Male inherits double the amount of the female because males are responsible for the family expenses. Female is not responsible to pay any expenses even if she is rich and her expenses is the responsibility of the closest male relative.
    - B. Presence of the son in particular family will limit the inheritance to the member of that particular family. In the absence of a son, the inheritance will be distributed to the far relatives.  
So A & B showed that the reassigned person will loose 50% of his share and if he is the only son, his reassignment will affect the shares of the members of his particular family.
  5. Homosexual marriage is not allowed. The reassignment will lead to homosexual marriage.
- \* Particular family means the husband and his wife, sons, daughters, grandfather and grandmother.

**CONCLUSION :**

We presented the pattern of intersex in our area and our experience in surgical correction of male and female genitalia with discussion of the ethical aspect in the sex assignment in the view of religious and social circumstances in our community and the changing trends in other communities, the conclusion of this was to support sex correction procedures and not reassignment.



**REFERENCES**

1. Blyth B, Churchill BM, Houle A, McLorie GA Intersex: In Gillenwater J, Grayhack J, Howards S, Dukett J eds. Adult and Paediatric Urology St. Louis, Mosby Year Book Inc. 1991:2141-2171.
2. Churchill BM, McLorie GA Intersex: Basis of clinical decision. Acta Urol Belg 57:625-646,1899.
3. Donahoe P. The diagnosis and treatment of infants with intersex abnormalities. Paediatr Clin North Am 34:1333-1348, 1987.
4. Pagon R. Diagnostic approach to newborn with ambiguous genitalia. Pediatr Clin North Am 34:1019-1031,1987.
5. Dukett J. Hypospadias In: Gillenwater J Grayhack J, Howards S, Dukett J eds. Adult and Paediatric Urology St. Louis, Mosby Year Book Inc. 1991:2103-2140.
6. Eberle J, Bartsch G. Posterior Hypospadias In: Eicher Wikubli F, Herms V eds. Plastic surgery in the surgically handicapped. Berlin: Springer-Verlag 1989:23-33.
7. Horton CE, Vorstman B, Teasley Diwinslow B, Hidden penis release. Adjunctive suprapubic lipectomy. Ann Plast Surg 19:131-134,1987.
8. Gilbert DA, Horton CE, Terzis JK et al. New concepts in phallic reconstruction. Ann Plast Surg 18:128-136,1987.
9. Jamal Y, Meshref S, Jamal H. Surgery of congenital adrenogenital hyperplasia In: Lutfi A. (ed). Proceeding of the 4th Congress of Arab Association of Pediatric Surgeons. Dubai, 1993:38-46.
10. Eicher W. The inverted penis skin technique in male to female transsexuals In: Eicher Wikubli F, Herm V eds. Plastic surgery in the sexually handicapped. Berlin: Springer-Verlag 1989:91-97.
11. Luks FI, Hansbrough F, Klotz DH et al. Early Gender assignment in true hermaphroditism. J Pediat Surg 23:1122-1126,1988.
12. Sharp RJ, Holder TM, Campbell P, et al: Neonatal genital reconstruction. J Pediat Surg, 22:168-171, 1987.
13. Reilly JM, Woodhouse CRJ. Small penis and male sexual role. J Urol 142:569-571, 1989.
14. Van seters AP, Slob AK. Mutually gratifying heterosexual relationship with micropenis of husband. J Sex Marital Ther 14:98-107,1988.

**ESTIMATION OF TESTICULAR VOLUME AND DETECTION OF ATROPHIC CHANGES FOR FORECASTING FUTURE SPERMATOGENESIS IN UNILATERAL UNDESCENDED TESTIS**

*Ul Hasan N, Abdul Shakoor K, Lashari I*

**ABSTRACT :**

Operative management of undescended testis (UDT) is based on assumption that by bringing down the testis into the scrotum will prevent the further progress of the degenerative changes which follow the arrest of its descent. The operation also restores the normal anatomy and thus confidence of the patient. So far, there is no parameter by which a surgeon operating upon an undescended testis, except by naked eye examination judge the quality of the testis and explain to parents its future functional capability. In a series of 18 patients of unilateral U.D.T., volume estimation of both the undescended and normally descended testis were made for comparison. At the same time testicular biopsy for undescended testis was taken to assess the atrophic changes under light microscopy. It was noted that the undescended testis in the majority of patients was less than 50% in volume of the normally descended testis. All of the biopsy specimen, showed various grades of atrophy. The atrophic changes were found to be minimal at the age of one year. These changes were more marked if the testis was found in the preperitoneal or high canalicular position. There was no correlation between the age of the patient, volume of the testis, its anatomical location with grade of the atrophy, therefore each case has to be individually assessed.

**Index Words :** Undescended testis unilateral, volume of, biopsy

**INTRODUCTION :**

The objective while operating upon the undescended testis are, firstly to safely place the undescended testis into the scrotum and secondly by doing so to stop the progressive atrophic changes that follow the process of non-descent and thus, to try to preserve the future spermatogenetic function of the testis. Presently the surgeons are handicapped in assessing the quality of the undescended testis which is being subjected to surgery, except by naked eye inspection. Therefore at the time of surgery or immediately after operation the surgeon is not in a position to forecast its future spermatogenetic activity. Only after attainment of puberty the volume of testis can be estimated with the help of the Prader Orchidometer, with doubtful accuracy<sup>(1)</sup>.

Correspondence to : Prof. Nizam ul Hasan, 54/1, 10th Street, Phase V, Defence Housing Society, Karachi 75500, Pakistan